

Use of therapeutic sealants on occlusal surfaces

UPDATE

Uso de sellantes terapéuticos en superficies oclusales

Uso de selantes terapêuticos em superfícies oclusais

Abstract

The indication of the use of sealants on occlusal surfaces has changed in the last 20 years. In the past, occlusal surfaces were sealed to prevent the development of carious lesions, however, currently sealants are also used for therapeutic purposes, trying to stop active carious lesions. Formerly, carious lesions were treated with surgical interventions, currently a non-surgical and less invasive treatment is imposed, provided that the extension of the lesion allows it, seeking the preservation of the dental structure throughout the cycle of life of the individual. The therapeutic approach must evolve to provide solutions adapted to the needs of patients, that are easy to implement and whose effectiveness is supported by scientific evidence. This review work aims to analyze the available evidence regarding the use of sealants for therapeutic purposes in active carious lesions in occlusal surfaces. A revision of the available literature in the Pubmed and SciELO databases published from 2006 to 2024 was carried out.

Current evidence indicates that the application of sealants in incipient active carious lesions on occlusal faces is an efficient and safe treatment to stop the progression of such lesions. Clear criteria must be established when selecting the use of sealant as treatment for carious lesions. In active carious lesions of the occlusal surfaces ICDAS 1,2 y 3 and 4 where the extension is limited to the external third of the dentin based on the radiography, sealants are effective, efficient and safe, therapeutic sealing is an excellent treatment to stop the progression of incipient carious lesions. In ICDAS 4 lesions that extend to the inner third of the dentin and in ICDAS 5 and 6, restorative treatment is indicated.

 Verónica Cueto Rostom ¹

CORRESPONDENCE

Verónica Cueto:

veronicacueto2505@gmail.com

Recibido: July 3, 2024

Aceptación: September 16, 2024



Key words: sealants, early carious lesion, pits and fissures

¹ Profesora Adjunta de la Cátedra de Operatoria Dental I de la Facultad de Odontología de la Universidad de la República

Resumen

La indicación del uso de sellantes en las superficies oclusales ha cambiado en los últimos 20 años. Actualmente los sellantes se utilizan con fines terapéuticos, intentando detener las lesiones cariosas activas, se impone un tratamiento no quirúrgico y mínimamente invasivo siempre que la extensión de la lesión así lo permita, buscando la preservación de la estructura dental a lo largo del ciclo de vida del individuo. Este trabajo de revisión tiene como objetivo analizar la evidencia disponible respecto al uso de los sellantes con fines terapéuticos en lesiones cariosas activas en superficies oclusales. Se realizó una revisión de la literatura disponible en las bases de datos Pubmed y SciELO, publicados desde el año 2006 al 2024. La evidencia actual indica que la aplicación de sellantes en lesiones cariosas activas incipientes en caras oclusales es un tratamiento efectivo y seguro para detener la progresión de dichas lesiones. Se deben establecer criterios claros a la hora de seleccionar el uso de sellantes como tratamiento de lesiones cariosas. En las lesiones cariosas activas de las superficies oclusales ICDAS 1, 2, 3 y en ICDAS 4 donde la extensión de la lesión se limita al tercio externo dentinario, (basado en la radiografía) los sellantes son efectivos, eficaces y seguros, el sellado terapéutico es un excelente tratamiento para detener la progresión de las lesiones cariosas incipientes. En las lesiones de ICDAS 4 que se extienden al tercio interno dentinario y en ICDAS 5 y 6 el tratamiento restaurador es el indicado.

Palabras clave: sellantes, lesiones cariosas incipientes, fosas y fisuras

Introduction

Despite advancements in the understanding of its etio-pathogenesis and the efforts made in recent decades to control it, dental caries remains the most prevalent chronic non-communicable disease worldwide. In recent years, particular emphasis has been placed on preventive strategies, early diagnosis, and timely treatment of early-stage lesions to arrest their progression, thus delaying or preventing the restorative cycle of the tooth. Additionally, more people are retaining their natural teeth into old age, which, when restorations are performed, requires ongoing dental intervention for their maintenance. Consequently, non-restorative treatment options have emerged as promising alternatives⁽¹⁻³⁾.

Fissure sealants were developed in the 1960s, and

Resumo

A indicação do uso de selantes em superfícies oclusais mudou nos últimos 20 anos. Atualmente os selantes são utilizados para fins terapêuticos, tentando estancar lesões de cárie ativas, sendo imposto um tratamento não cirúrgico e minimamente invasivo sempre que a extensão da lesão o permite, procurando a preservação da estrutura dentária ao longo do ciclo de vida do indivíduo. Esta revisão tem como obje lesões cariosas ativas em superfícies oclusais. Foi realizada uma revisão da literatura disponível nas bases de dados Pubmed e SciELO, publicada de 2006 a 2024.

Evidências atuais indicam que a aplicação de selantes em lesões de cárie ativas incipientes em superfícies oclusais é um tratamento eficaz e seguro para interromper a progressão da doença. essas lesões. Critérios claros devem ser estabelecidos ao selecionar o uso de selantes como tratamento para lesões cariosas. Nas lesões cariosas ativas das superfícies oclusais ICDAS 1, 2 e 3 e no ICDAS 4 onde a extensão é limitada ao terço externo da dentina, com base na radiografia, os selantes são eficazes,eficientes e seguros, o selamento terapêutico é um excelente tratamento para interromper a progressão de lesões cariosas incipientes. Nas lesões ICDAS 4 que se estendem até o terço interno da dentina e nas ICDAS 5 e 6 o tratamento restaurador está indicado.

Palavras-chave: selantes, lesão cariosa precoce, fosetas e fissuras

their preventive efficacy has been extensively documented. Their use has been the subject of multiple systematic reviews^(2,4,5,6). In dentistry, the term “sealant” refers to a clinical procedure in which a material is applied to the pits and fissures of teeth, forming a micro-mechanically bonded protective layer on the adamantine surface. This forms a physical barrier, typically using highly flowable resins that adhere to enamel prisms, preventing contact between the host and the biofilm⁽⁷⁾.

Currently, the ICDAS system (International Caries Detection and Assessment System) is used to classify carious lesions. There are seven stages (codes), ranging from a healthy tooth to one where more than half of the surface has been lost to caries. Code 0 represents a

healthy tooth; codes 1 and 2 represent the first visible changes on the dry and wet enamel surface, respectively; code 3 corresponds to localized enamel breakdown; code 4 to the presence of underlying dentin shadowing; and codes 5 and 6 to cavitated lesions in dentin involving less than 50% and more than 50% of the tooth surface, respectively.

Sealants are part of the therapeutic armamentarium of minimally invasive dentistry and are referred to as therapeutic sealants. Applying sealants to carious lesions significantly reduces bacterial counts, and due to the lack of nutrients, the remaining viable bacteria exhibit low cariogenic potential^(1,8,9,10,11,12). This review aims to analyze the use of sealants for therapeutic purposes in active carious lesions on occlusal surfaces and to determine in which types of lesions their use is both effective and safe.

A comprehensive narrative review of the available literature was conducted using the PubMed and SciELO databases, covering publications from 2010 to 2024. The following English descriptors were used: sealants, pits and fissures, early carious lesions. In SciELO, the additional descriptors sellantes, fosas y fisuras, and lesiones cariosas incipientes were included. Articles published in English, Spanish, and Portuguese were considered. Exclusion criteria included articles published before 2006, case reports, and in vitro studies. A total of 153 articles were retrieved, and their titles and abstracts were read. Articles focusing on preventive sealants were discarded, and only those discussing therapeutic sealants published after 2006 were included, totaling 44 articles. The search was further supplemented by reviewing the references cited in these articles. Duplicate articles were eliminated, resulting in 27 selected articles, along with two textbooks.

Development

Over the past 20 years, the indication for resin sealant use on occlusal surfaces has changed. Previously, occlusal surfaces were sealed to prevent the development of carious lesions, and were called preventive sealants. In cases where sealants are placed over carious lesions, the term therapeutic sealants is more accurate. Today, sealants are primarily used for therapeutic purposes, aimed at arresting incipient active lesions^(6,11,12). For this therapeutic use of sealants, it is essential to assess the extent and activity of the lesion. If the lesion is inactive (**Figure 1** and **2**), treatment is likely unnecessary. However, if the lesion is active, sealant placement can be an excellent option for the patient⁽¹²⁾.

Professionals who claim they would never apply sealants to carious lesions have likely done so inadvertently on many occasions, especially on occlusal surfaces where diagnostic methods may lack accuracy⁽²⁾. Active incip-

ient occlusal lesions can be managed in various ways: by monitoring their progression with specific brushing instructions and dietary guidance, through remineralization, or by applying sealants^(1,12).

Non-invasive strategies, including oral hygiene instructions, dietary advice, and professional applications of fluoride varnish, are more effective on smooth surfaces, where biofilm control is easier to maintain due to their anatomical characteristics. The application of sealants on incipient carious lesions on occlusal surfaces is the indicated treatment^(5,8,11,12,13,14,15). Furthermore, when cavitation is present, biofilm removal becomes difficult, and when it remains trapped in the cavity, the lesion will likely progress (active lesion). Carious lesions on smooth surfaces can be reduced to a greater extent with non-invasive strategies compared to lesions on occlusal surfaces⁽⁸⁾.

Sufficient evidence indicates that applying sealants to incipient carious lesions on occlusal surfaces is an effective treatment. It should be clearly established which types of lesions can be treated with non-invasive methods, which should be sealed, and which require restorative treatment⁽¹²⁾.

In 2012, Bakhshandeh published a study evaluating carious lesions on occlusal surfaces: 10.8% of the sealed carious lesions had progressed, compared to 51.8% of the unsealed lesions⁽¹¹⁾. Consequently, sealants are now indicated preventively for high-risk patients and therapeutically for incipient carious lesions on occlusal surfaces^(11,12).

Several studies indicate that carious lesions under a sealant do not progress as long as the sealant remains intact and adherent. It has also been observed that the number and viability of microorganisms in infected dentin are significantly reduced due to the lack of access to nutrients^(9,11,16). In 2008, Griffin published an evidence review aimed at examining the effect of bacterial colony counts in sealed carious lesions. The findings indicated that sealants effectively reduced the bacterial presence within lesions, with this reduction increasing over time. The longer the sealant remained on the occlusal surface, the fewer bacteria were detected. By blocking nutrient access, lesion progression was effectively arrested. In sealed lesions, 47% had viable bacteria, compared to 87% in unsealed lesions. When excluding lesions with deep dentin extension, 27% of sealed lesions had viable bacteria, versus 83% in unsealed lesions⁽⁹⁾.

In 2010⁽¹³⁾ and 2012⁽¹⁴⁾, Borges et al. published two randomized controlled clinical trials at 12 and 36 months, respectively, yielding similar results. In the 36-month trial, they found that 96% of lesions treated with only oral hygiene instructions progressed, compared to just 3.8% of sealed lesions, with caries progression in treated teeth occurring upon sealant loss. In this study, sixty teeth with non-cavitated occlusal dentin caries, extending maxi-

mally to the middle third of the dentin, were selected. The patients were randomly divided into two groups. Patients in the experimental group received oral hygiene instructions and a fissure sealant, while those in the control group received oral hygiene instructions. Caries progression and sealant loss were monitored over 36 months through clinical and radiographic examinations. Results indicated that clinical and radiographic progression of carious lesions was significantly more frequent in the control group than in the experimental group. Three teeth lost their sealant and showed caries progression, which became evident only at the 12-month follow-up. The study concluded that pit and fissure sealants effectively arrest dentin caries lesions of moderate extent over 36 months ⁽¹⁴⁾.

Multiple systematic reviews support the efficacy of sealants for treating occlusal carious lesions. A systematic review of randomized clinical trials published in 2016 concluded that the available evidence suggests sealants are effective and safe for preventing or arresting the progression of non-cavitated carious lesions in both permanent and primary molars, compared to either a control group without sealants or fluoride varnish application ⁽⁵⁾. In 2019, Urquhart et al. conducted another systematic review and meta-analysis of non-restorative treatments for carious lesions, concluding that fluoride varnishes for free surfaces and sealants for occlusal surfaces comprise the most effective strategy for treating non-cavitated lesions ⁽¹⁵⁾.

Another systematic review published in 2022 examined the effectiveness of non-restorative treatments for both cavitated and non-cavitated carious lesions in adults and children. This review focused on primary and permanent dentition diagnosed through radiographs and visual-tactile assessments, with follow-up periods ranging from 6 to 84 months. It concluded that pit and fissure sealants are effective strategies for preventing the onset of carious lesions and arresting them at early stages ⁽¹⁷⁾.

Another article published in 2023 established that non-invasive strategies—including oral hygiene instructions, dietary advice, and professional fluoride varnish applications—are most effective on smooth surfaces. Carious lesions on smooth surfaces show greater reduction with non-invasive strategies compared to lesions on occlusal surfaces ⁽⁸⁾. (**Table 1**)

Although the literature agrees that early-stage (non-cavitated) carious lesions classified as ICDAS 1 and 2 can be treated with sealants, there are fewer studies supporting their use in lesions with localized enamel breakage, ICDAS 3 (microcavitated), for arresting progression (**Figure 3**). A randomized controlled trial published in 2019 concluded that sealing ICDAS 3 carious lesions in

permanent molars appears to effectively halt their progression. Moreover, this approach preserves tooth structure, reduces chair time, alleviates fear, cuts costs, and broadens access to dental care ⁽³⁾.

The American Dental Association (ADA) states that while sealants are commonly associated with younger patients, they are also used for both preventive and therapeutic applications in adults, as outlined in their evidence-based recommendations. Applying pit and fissure sealants significantly reduces the rate of progression in non-cavitated carious lesions compared to unsealed teeth ⁽⁶⁾. Sealing enamel caries and potential occlusal dentinal caries is the most effective approach, provided maintenance of the sealed surfaces is ensured. However, there is disagreement among authors on the depth of dentin involvement at which sealing remains viable and when restoration becomes essential ⁽¹⁰⁾.

Clinical and radiographic diagnosis is essential to determine which lesions can be sealed and which require restorative treatment, thus defining lesion extent. According to the ICDAS classification, primary carious lesions are categorized into six severity stages (codes), ranging from a healthy tooth to one with extensive lesions and visible dentin covering more than 50% of the surface. For teeth classified as ICDAS 0, a healthy tooth may be treated with a preventive sealant if the assessment of the tooth and the patient indicates the need (in patients with caries activity or at high risk). For teeth with ICDAS codes 1, 2, and 3 (initial visual change in enamel, distinct visual change in enamel, and localized enamel breakage, respectively), therapeutic sealants are indicated. This approach has support from various authors ^(4, 6, 11, 12, 14, 18, 19).

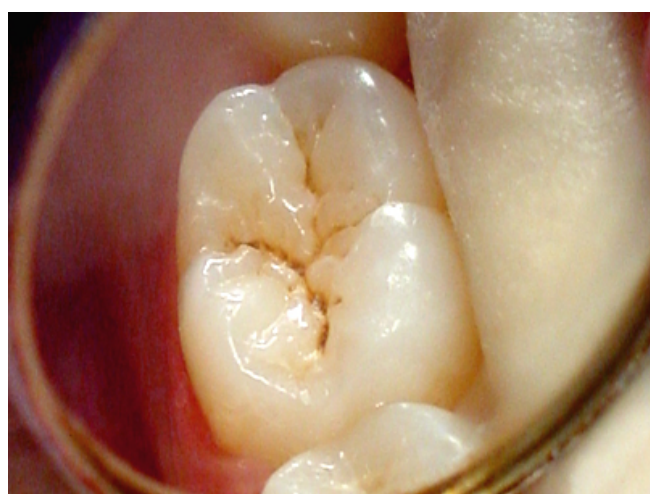

Figure 1. ICDAS 1 inactive.
First visual change in the enamel.

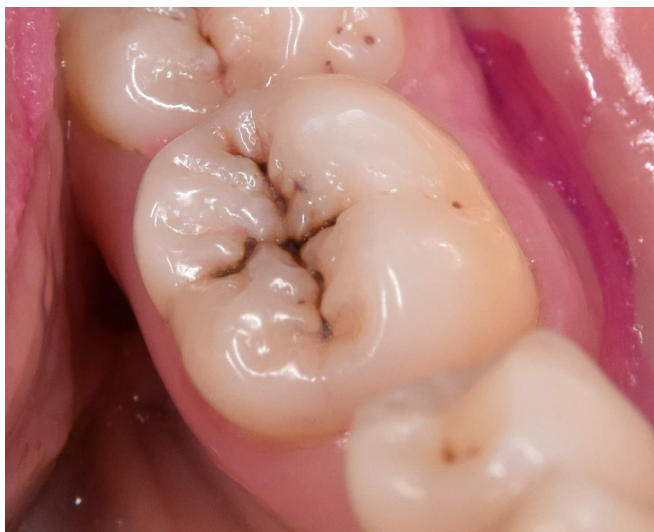


Figure 2. ICDAS 1 inactive.

First visual change in the enamel..

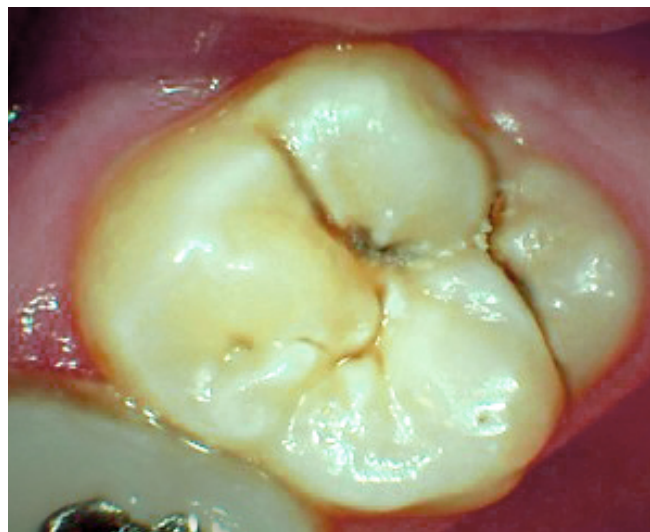

Figure 3. ICDAS 3 active.

Localized enamel breakdown, microcavitation, microbial plaque accumulation.

A randomized clinical trial published in 2021 comparing non-invasive (fluoride varnish application) and micro-invasive (sealants) treatments to arrest active occlusal caries lesions in permanent molars concluded that for ICDAS 1, 2, and 3 lesions, sealing is more effective than varnish application at arresting lesion progression. At 12 months, 22% of lesions treated with fluoride varnish and only 3% of those treated with sealant remained active ⁽¹⁶⁾.

Another randomized controlled clinical trial, published in 2018, evaluated the efficacy of sealing carious dentin on lesion progression in primary molars over a two-year period. Children with primary molars showing occlusal caries reaching the outer half of the dentin were randomized into two groups: one group treated caries lesions with flowable resin sealant, while the other received partial caries removal followed by restoration. Clinical success was assessed based on United States Public Health Service (USPHS) criteria, along with radiographic analysis of lesion progression. The study concluded that sealing carious dentin is a viable option in dentistry, demonstrating comparable clinical success and no radiographic differences when compared to partial caries removal followed by restoration. The authors recommend sealing carious lesions that extend to the outer half of the dentin with resin-based sealants ⁽²⁰⁾.

In another clinical trial published in 2012, 72 occlusal carious lesions were sealed in adult patients who had been referred for restorative treatment of these lesions, with a maximum radiographically assessed depth reach-

ing the middle third of the dentin. Lesions limited to the enamel were excluded. This study aimed to evaluate the potential for arresting occlusal caries lesions in adults using a sealant and to assess the radiographic outcomes of progression, arrest, and regression in sealed lesions. Results showed that 14% of the sealants required repair or replacement due to failure, while 6% of the sealed lesions were restored due to lesion progression. Radiographic evaluation revealed less than 10% of sealants showed lesion progression, 2% demonstrated regression, and 88% showed no change beneath the sealant. Most lesions were successfully arrested with sealant application, suggesting a potential expansion of criteria for sealing occlusal caries in adults. However, the study concluded that lack of patient follow-up poses concerns when considering broader non-surgical intervention criteria for carious lesions ⁽²¹⁾. As such, conventional excavation and restoration of occlusal lesions may be postponed as long as the sealant remains intact and adheres well to the tooth structure ^(11, 21).

Another randomized clinical trial from 2021 examined the efficacy of non-invasive and micro-invasive treatments in arresting ICDAS 1 to 3 carious lesions. The sample was randomly assigned to two treatment groups: one using resin-modified glass ionomer cement sealer, and the other applying topical fluoride varnish over four weeks. After 12 months, 22% of lesions treated with fluoride varnish and 3% of those treated with sealant remained active. The likelihood of stopping active enamel caries after sealant application was 8.85 times higher

TABLE I.

| AUTHOR | YEAR | ICDAS | STUDY TYPE | CONCLUSIONS |
|---------------------------|------|--------------------------------------------------------|---------------------------------------|-------------------------------------------------------------------------------------------------------------------------------------------------------------------------------------------|
| Borges ⁽¹³⁾ | 2010 | 4 with maximum extension to the middle third of dentin | Controlled clinical trial (12 months) | Sealant proved effective in arresting medium-depth dentin lesions after 12 months. |
| Borges ⁽¹⁴⁾ | 2012 | 4 with maximum extension to the middle third of dentin | Controlled clinical trial (36 months) | Sealant proved effective in arresting medium-depth dentin lesions after 36 months. |
| Boniak ⁽²¹⁾ | 2012 | 4 | Clinical trial | 88% of lesions were successfully arrested with sealant application. |
| Wright ⁽⁵⁾ | 2016 | 1 and 2 | Systematic review of clinical trials | Sealants are safe for preventing or arresting carious lesions compared to control without sealants or with varnishes. |
| Ribeiro ⁽²⁰⁾ | 2018 | 4 | Randomized controlled clinical trial | Sealing carious dentin can be used in dentistry, as it did not increase children's anxiety, reduced chair time, and showed a clinical success rate comparable to removal and restoration. |
| Urquhart ⁽¹⁵⁾ | 2019 | 1 and 2 | Systematic review and meta-analysis | Application of varnishes for free surfaces and sealants for occlusal surfaces is the most effective strategy for these types of lesions. |
| Rodríguez ⁽¹⁶⁾ | 2021 | 1, 2 and 3 | Trial | Sealing is a more effective treatment than applying fluoride varnish for arresting these lesions. |
| Cabalén ⁽¹⁷⁾ | 2022 | 1, 2, 3 and 4 | Systematic review | Sealants are described as effective strategies for arresting carious lesions in their early stages. |
| Da Silva ⁽⁸⁾ | 2023 | 1, 2 and 3 | Longitudinal retrospective study | Cariou lesions on smooth surfaces can be reduced to a greater extent with non-invasive strategies compared to lesions on occlusal surfaces. |

Comparative table of published studies by author, year, ICDAS code, study type, and conclusions.

than with fluoride varnish ($p = 0.01$). Sealants are more effective than fluoride varnish for arresting carious enamel lesions on the occlusal surfaces of erupting permanent molars ⁽¹⁶⁾.

A systematic review and meta-analysis on sealant use published in 2021 concluded that sealants are recom-

mended for permanent molars to reduce the incidence of occlusal caries, arrest lesion progression, and help alleviate disparities in oral health among individuals from different socioeconomic backgrounds ⁽²²⁾.

Discussion

Although scientific evidence supports the therapeutic use of sealants, this practice has not been widely adopted among dentists. There is concern that sealing may lead to underestimating the true histologic extent of a lesion, resulting in inadequate treatment ⁽¹¹⁾. For ICDAS code 4 (Figure 4), showing an underlying shadow from the dentin, there is controversy: some authors consider sealants an option, while others argue that if the lesion is significantly advanced in the dentin, a surgical approach is necessary ^(1,6). The challenge with ICDAS 4 lesions is the high variability in dentin involvement. A 2013 study aimed to investigate the radiographic patterns of these lesions in permanent molars and to assess the association between enamel involvement and the radiographic characteristics of these lesions. The study found that most ICDAS 4 lesions did not present radiolucent images in the dentin (67%), and only 18% showed radiolucency in the dentin despite the presence of clinically evident dark shadows. The study concluded that a clinical classification of a caries lesion as ICDAS 4 may vary in terms of dentin extent. These results suggest that radiographic examination is necessary for decision-making in the management of these lesions ⁽²³⁾.

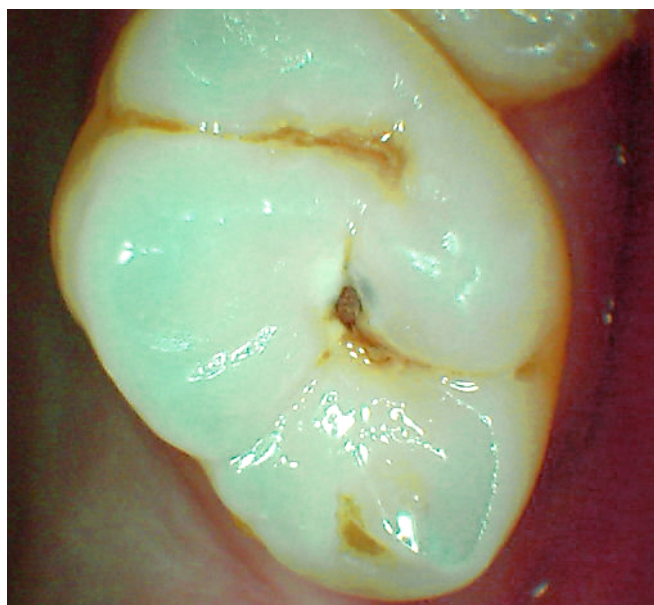


Figure 4. ICDAS 4.
Underlying shadow from the dentin

Another 2012 randomized controlled clinical trial studied the sealing of cavitated occlusal carious lesions in primary molar dentin. The study concluded that both sealing and restoration effectively arrested caries progression over

a two-year period. However, the survival rates of sealants on ICDAS 5 occlusal lesions in primary molars were lower than those of restorations. Smaller lesions were less likely to fail after one year, but differences became statistically significant after two years ⁽²⁴⁾.

The extent of dental involvement for which sealants are appropriate, compared to when restorative treatment is necessary, must be clearly defined. First, the amount of affected tissue and the strength of the remaining dental structure should be evaluated. Next, assess the mechanical demands placed on dental materials, which increase with the severity of the lesion. Advanced lesions require materials with specific characteristics, such as wear resistance, tensile strength, and compressive strength—qualities that traditional sealants cannot provide due to their composition ⁽¹⁾. In certain cases, restorative treatment becomes unavoidable, and it is recommended for ICDAS 5 and 6 lesions ^(1,2,11). Another study evaluated sealant failures over a 2–3-year period. Out of 10 recorded failures, 9 were linked to the clinical performance of the sealants: 7 cases exhibited loss of retention, while 2 cases had partial retention (annual resin sealant failure rate of 7.4%), which results in a higher frequency of retreatments in this group. Together, these findings suggest that successful use of dental sealants to manage caries lesions requires patient commitment to attend follow-up appointments to assess the need for sealant repairs ⁽²¹⁾.

The lack of caries progression in the majority of sealed teeth reinforces the understanding that sealants form a physical barrier, isolating the lesion from the oral environment and restricting nutrient access for cariogenic bacteria, thereby controlling the carious lesion's progression ^(1,10). Current evidence indicates that for carious lesions limited to the outer third of the dentin (based on radiography), sealing is significantly more effective than non-invasive treatments such as fluoride varnish or dietary and hygiene guidance ^(1,21,25). However, since the arrest of caries heavily depends on sealant retention, researchers should seek ways to enhance the mechanical durability of these materials. Using flowable resin as a fissure sealant may be an effective option for teeth with occlusal dentin caries, as its composition offers superior mechanical properties compared to traditional sealants ^(21,26).

A two-year prospective randomized controlled clinical trial published in 2024 compared the effectiveness of micro-operative treatment (sealing) in arresting caries with surgical treatment followed by restoration using flowable resin. The clinical progression of dental caries and material retention were the results used for comparing the groups. Although sealing microcavitated carious lesions in the first permanent molar showed lower retention rates than resin composite restorations, both treatments

effectively arrested the progression of caries over the two-year period. The cumulative retention rate was 57.5% in the sealant group and 92.1% in the flowable composite group, with significant differences ($p < 0.001$). Sealants had a higher risk of retention failure compared to restorations with flowable resin ⁽²⁷⁾.

Over the years, various materials have been reported in the literature for sealing occlusal surfaces, with resin-based and ionomeric sealants standing out. Sealant effectiveness is linked to long-term retention rates. Sealant effectiveness is linked to long-term retention rates: resin-based sealants generally show high retention, typically above 90% at one year. At 12 to 24 months, resin sealants achieve an average full retention rate of 80% of cases. After 4 to 5 years, most studies reported a 70% retention rate, dropping to 39% at 9 years ⁽⁴⁾. Sealant retention loss is estimated at 5-10% per year; so regular monitoring and replacement are recommended when retention fails. Sealant failure is mostly due to inadequate moisture control and occlusal forces acting on the sealant, underscoring the importance of thorough occlusal assessment post-polymerization or setting ^(2,18,26).

In a meta-analysis published in 2012, the retention rates of various sealant materials were compared, yielding the following results: self-cured sealants had the longest observation period (up to 20 years), with a 5-year retention rate of 64.7%; light-cured resin sealants had a retention rate of 83.8%, and glass ionomer cement-based sealants showed significantly lower retention rates at five years, with intact sealants retained at only 15% after 2 years, decreasing to 7% after 3 years, and dropping to 5% at 5 years. The authors concluded that resin-based sealants, whether self- or light-cured, are recommended. Glass ionomer cement-based sealants, due to their significantly lower retention rates, are not advised for routine clinical use ⁽²⁸⁾. Several authors agree that the retention rate of glass ionomer-based sealants is low; thus, they are recommended only for specific clinical situations where conventional composite resin-based sealants cannot be applied, such as with erupting teeth ^(2,4,12,28,29). According to ADA guidelines from 2008, resin-based sealants are preferred, with ionomer sealants recommended only when moisture control limits the use of resin-based options ⁽⁶⁾.

Conclusions

There are two non-invasive professional therapeutic approaches to treating carious lesions: remineralization, which uses chemical agents to promote hard tissue regeneration (fluoride being the most widely used agent), and the application of therapeutic sealants, which aim to arrest lesion progression by depriving bacteria of nutrients. Fluoride application is more effective on free surfaces.

Current evidence shows that sealants are effective, efficient, and safe for active carious lesions on occlusal surfaces categorized as ICDAS 1, 2, and 3, as well as ICDAS 4 lesions confined to the outer third of dentin (as determined radiographically); therapeutic sealants are an excellent treatment option to prevent the progression of incipient carious lesions. For ICDAS 5 and 6 lesions, restorative treatment is recommended.

To determine which lesions can be sealed versus those requiring restorative treatment, it is essential that the clinical and radiographic diagnosis is as precise as possible.

Invasive treatment should only be performed when attempts to halt lesion progression have failed or when the remaining dental tissue is fragile and at risk of fracture due to lesion progression in the dentin.

The lack of progression in most sealed teeth supports the understanding that sealants form a physical barrier, isolating the carious lesion from the oral environment and restricting nutrient access to cariogenic bacteria, thereby controlling lesion progression. Using sealants to treat carious lesions requires ongoing monitoring, with an estimated 5-10% needing repair or replacement each year. The success of this treatment depends on the sealant remaining adhered and intact on the occlusal surface. Reapplication of any lost or fractured sealant is necessary to ensure the long-term success of this treatment. Patients who do not attend follow-up appointments pose a concern when considering an expanded criteria for non-surgical intervention of carious lesions.

REFERENCES

1. Schewendickde F, Frencken JE, Bjorndal L et al. Managing Carious Lesions: consensus recommendations on carious tissue removal. *Advances in Dental Research* 2016; 28(2):58-67.
2. Eggertsson H. Sellado de fisuras en Meyer-Lueckel H, Paris S, Ekstrand K. Manejo de la Caries en Ciencia y Práctica Clínica. 1era.ed. Caracas: Amolca.2015. p.226-238.
3. Muñoz-Sandoval , Gambetta-Tessini , Giacaman. Microcavitated (ICDAS 3) carious lesion arrest with resin or glass ionomer sealants in first permanent molars: A randomized controlled trial. *J Dent.* 2019;(5): 88:103-163.
4. Ahovuo-Saloranta A, Forss H, Walsh T, Nordblad A, Mäkelä M, Worthington HV. Pit and fissure sealants for preventing dental decay in permanent teeth. *Cochrane Database of Systematic Reviews* 2017;(7):1-187.
5. Wright JT, Tampi MP, Graham L. Sealants for preventing and arresting pit and fissure occlusal caries in primary and permanent molars. A systematic review of randomized controlled trials a report of the American Dental Association and the American Academy of Pediatric Dentistry. *J Am Dent Assoc* 2016;147(8): 631-645.
6. Beachamp J, Simonsen R et al. Evidence-based clinical recommendations for the use of pit and fissure sealants. A report of the ADA Council on Scientific Affairs. *JADA* 2008; 139(3): 257-268.
7. Macchi R. Selladores de fosas y fisuras en Materiales Dentales Macchi R.4ta ed. Buenos Aires: Panamericana,2007 p.117-123.
8. Da Silva A, Plotnik D, Muñoz. M. Effectiveness of non-operative approaches in active enamel carious lesions: a retrospective longitudinal study. *Braz Oral Res.* 2023;37(3):1-10.
9. Griffin S, Kohn W, Gooch B. The effect of dental sealants on bacteria levels in caries lesions: a review of the evidence. *J Am Dent Assoc* 2008;139(3):271-8.
10. Bader J, Shugars D. The evidence supporting Alternative Management Strategies for early occlusal caries and suspected occlusal dentinal caries. *Journal of Evidence –Based Dental Practice* 2006; 6(1):91-100.
11. Bakhshandeh A. Sealing occlusal caries lesions in adults referred for restorative treatment :2-3 years of follow-up. *Clin Oral Invest* 2012;16(2):521-9.
12. Holmgren C, Graucher C, Decerle N. Minimal Intervention dentistry II: part 3. Management of non-cavitated (initial) occlusal caries lesions –non invasive approaches though remineralization and therapeutic sealant. *British Dental Journal* 2014; 216(5):237-243.
13. Borges B C, Campos G B, da Silveira A D, de Lima K C, Pinheiro I V. Efficacy of a pit and fissure sealant in arresting dentin non-cavitated caries: a 1 year follow up randomized, single-blind, controlled clinical trial. *Am J Dent* 2010; 23(6): 311-316.
14. Borges BC, de Souza Borges J. Arrest of non cavitates dentinal occlusal caries by sealing pits and fissures; a 36-month, randomized controlled clinical trial. *Int Dent J.* 2012; 62(5): 251-255.
15. Urquhart O, Tampi MP, Pilcher M. Slayton R. Nonrestorative Treatments for Caries: Systematic Review and Network Meta-analysis. *Journal of Dental Research* 2019; 98 (1):14–26.
16. Rodríguez J, Marchioro N. Non-invasive and micro-invasive treatments to arrest active occlusal carious lesions in erupting permanent molars: A randomized clinical trial. *Braz Oral Res* 2021; 35(7): 30-35.

17. Cabalén MB, Bono A, Burrow M. Nonrestorative Caries Treatment: A Systematic Review Update Review Int Dent J 2022 Dec;72(6):746-764.
18. Muller-Bolla M, Lupi-Peguner L. Retention of resin-based pit and fissure sealant a systematic review. Journal of Community Dentistry and Oral Epidemiology.2006;34(5)321-36.
19. Gore DR. The use of dental sealants in adults: a long – neglected preventive measure. Int J Dent Hygiene 2010;8(3):198-203.
20. Ribeiro K, Días C, Tomaz Wait T. Efficacy of sealing occlusal caries with a flowable composite in primary molars: A 2-year randomized controlled clinical trial. Randomized Controlled Trial J Dent 2018; 74(3):49-55.
21. Boniak Castillo L, De Souza Borges J. Arrest of non cavitated dentinal occlusal caries by sealing pits and fissures a 36- month randomized controlled clinical trial. International Dental Journal 2012;62(5): 251-255.
22. Lam PP, Sardana D, Lo EC, Yiu CK. Fissure sealants in a Nutshell. Evidence-based-evaluation of sealants. Effectiveness in caries prevention and arrest. J Evid Based Dent Pract. 2021; 21(3) 323-345.
23. Bertella N, Maltz M, Alves LS. Clinical and Radiographic diagnosis of underlying dark shadow from dentin (ICDAS 4) in permanent molars. Caries Research 2013;47(5):429-432.
24. Boniek C, Borges D. Efficacy of a non-drilling approaches to manage non-cavitated dentin occlusal caries in primary molars: a 12-month randomized controlled clinical Randomized Controlled Trial Int J Pediatr Dent 2012;22(1):44-51.
25. Bonetti D. Evidence not practiced: The underutilization of preventive fissure sealants. British Dental Journal 2014;216(7): 409-413.
26. Ugur E, Hande S, Batu C. Clinical comparison of a flowable composite and fissure sealant. A 24months split mouth, randomized and controlled study. Journal of Dentistry 2014; 42(2):149-157.
27. Wang Y, Pan T. Comparing the effectiveness of caries arrest by micro-operative treatment to operative treatment: A 2-year randomized controlled clinical trial. Clinical Oral Inv. March 2024; 28(4):222-232.
28. Kühnisch A, Mansmann U, Heinrich-Weltzien R, Reinhard H. Longevity of materials for pit and fissure sealing—Results from a meta-analysis. Dental materials 2012; 28(3):298-303.
29. Gore DR. The use of dental sealants in adults: a long – neglected preventive measure. Int J Dent Hygiene 2010; 8(3):198-203.

Conflict of Interest Statement

The author has no conflicts of interest in the publication of the article..

Funding source

The author declares not having funding source.

Authorship Contribution and Collaboration Statement

| FIRST AND LAST NAME | ACADEMIC COLLABORATION | | | | | | | | | | | | | |
|---------------------|------------------------|---|---|---|---|---|---|---|---|----|----|----|----|----|
| | 1 | 2 | 3 | 4 | 5 | 6 | 7 | 8 | 9 | 10 | 11 | 12 | 13 | 14 |
| Verónica Cueto | x | | x | x | x | x | x | x | x | x | | | | x |

- | | | | |
|----|----------------------------|-----|------------------------------------|
| 1. | Project Administration | 8. | Methodology |
| 2. | Funding Acquisition | 9. | Resources |
| 3. | Formal Analysis | 10. | Writing-Original Draft Preparation |
| 4. | Conceptualization | 11. | Software |
| 5. | Data Curation | 12. | Supervision |
| 6. | Writing - Review & Editing | 13. | Validation |
| 7. | Research | 14. | Visualization |

Acceptance Note:

This article was approved by the journal editor PhD. Dr. Vanesa Pereira-Prado.